

Development and Preliminary Validation of a Magnetic Resonance Imaging Joint Space Narrowing Score for Use in Rheumatoid Arthritis: Potential Adjunct to the OMERACT RA MRI Scoring System

MIKKEL ØSTERGAARD, PERNILLE BØYESEN, IRIS ESHED, FRÉDÉRIQUE GANDJBAKHCH, SIRI LILLEGRAVEN, PAUL BIRD, VIOLAINE FOLTZ, ANNELIES BOONEN, MARISSA LASSERE, KAY-GEERT HERMANN, ALLEN ANANDARAJAH, UFFE MØLLER DØHN, JANE FREESTON, CHARLES G. PETERFY, HARRY K. GENANT, ESPEN A. HAAVARDSHOLM, FIONA M. McQUEEN and PHILIP G. CONAGHAN

J Rheumatol 2011;38;2045-2050  
<http://www.jrheum.org/content/38/9/2045>

1. Sign up for our monthly e-table of contents  
<http://www.jrheum.org/cgi/alerts/etoc>
2. Information on Subscriptions  
<http://jrheum.com/subscribe.html>
3. Have us contact your library about access options  
[Refer\\_your\\_library@jrheum.com](mailto:Refer_your_library@jrheum.com)
4. Information on permissions/orders of reprints  
<http://jrheum.com/reprints.html>

*The Journal of Rheumatology* is a monthly international serial edited by Earl D. Silverman featuring research articles on clinical subjects from scientists working in rheumatology and related fields.

# Development and Preliminary Validation of a Magnetic Resonance Imaging Joint Space Narrowing Score for Use in Rheumatoid Arthritis: Potential Adjunct to the OMERACT RA MRI Scoring System

MIKKEL ØSTERGAARD, PERNILLE BØYESEN, IRIS ESHED, FRÉDÉRIQUE GANDJBAKHCH, SIRI LILLEGRAVEN, PAUL BIRD, VIOLAINE FOLTZ, ANNELIES BOONEN, MARISSA LASSERE, KAY-GEERT HERMANN, ALLEN ANANDARAJAH, UFFE MØLLER DØHN, JANE FREESTON, CHARLES G. PETERFY, HARRY K. GENANT, ESPEN A. HAAVARDSHOLM, FIONA M. McQUEEN, and PHILIP G. CONAGHAN

**ABSTRACT.** *Objective.* To develop and validate a magnetic resonance imaging (MRI) method of assessment of joint space narrowing (JSN) in rheumatoid arthritis (RA).

*Methods.* Phase A: JSN was scored 0–4 on MR images of 5 RA patients and 3 controls at 15 wrist sites and 2nd–5th metacarpophalangeal (MCP) joints by 8 readers (7 once, one twice), using a preliminary scoring system. Phase B: Image review, discussion, and consensus on JSN definition, and revised scoring system. Phase C: MR images of 15 RA patients and 4 controls were scored using revised system by 5 readers (4 once, one twice), and results compared with radiographs [Sharp-van der Heijde (SvdH) method].

*Results.* Phase A: Intraobserver agreement: intraclass correlation coefficient (ICC) = 0.99; smallest detectable difference (SDD, for mean of readings) = 2.8 JSN units (4.9% of observed maximal score). Interobserver agreement: ICC = 0.93; SDD = 6.4 JSN units (9.9%). Phase B: Agreement was reached on JSN definition (reduced joint space width compared to normal, as assessed in a slice perpendicular to the joint surface), and revised scoring system (0–4 at 17 wrist sites and 2nd–5th MCP; 0: none; 1: 1–33%; 2: 34–66%; 3: 67–99%; 4: ankylosis). Phase C: Intraobserver agreement: ICC = 0.90; SDD = 6.8 JSN units (11.0%). Interobserver agreement: ICC = 0.92 and SDD = 6.2 JSN units (8.7%). The correlation (ICC) with the SvdH radiographic JSN score of the wrist/hand was 0.77. Simplified approaches evaluating fewer joint spaces demonstrated similar reliability and correlation with radiographic scores.

*Conclusion.* An MRI scoring system of JSN in RA wrist and MCP joints was developed and showed construct validity and good intra- and interreader agreements. The system may, after further validation in longitudinal data sets, be useful as an outcome measure in RA. (J Rheumatol 2011;38:2045–50; doi:10.3899/jrheum.110422)

## Key Indexing Terms:

RHEUMATOID ARTHRITIS  
JOINT SPACE NARROWING

MAGNETIC RESONANCE IMAGING  
OUTCOME MEASURE

CARTILAGE  
RADIOGRAPHY

From the Department of Rheumatology, Copenhagen University Hospital at Glostrup, Copenhagen, Denmark; Department of Rheumatology, Diakonhjemmet Hospital, Oslo, Norway; Sheba Medical Center, Tel Aviv University, Tel Aviv, Israel; Department of Rheumatology, Pitié Salpêtrière Hospital, APHP, Université Paris 6-UPMC, Paris, France; Division of Medicine, University of NSW, Sydney, Australia; Maastricht University Medical Center, Maastricht, The Netherlands; Department of Radiology, Charité University Hospital, Berlin, Germany; Department of Allergy, Immunology and Rheumatology, University of Rochester Medical Center, Rochester, NY, USA; Section of Musculoskeletal Disease, University of Leeds and NIHR Leeds Musculoskeletal Biomedical Research Unit, UK; Spire Sciences LLC; University of California San Francisco, San Francisco, CA, USA; Synarc, Inc., San Francisco, USA; and Department of Molecular Medicine and Pathology, Faculty of Medicine and Health Sciences, University of Auckland, Auckland, New Zealand.

M. Østergaard, MD, PhD, DMSc, Professor of Rheumatology, Department of Rheumatology, Copenhagen University Hospitals at Hvidovre and Glostrup; P. Bøyesen, MD, PhD, Senior Registrar, Department of Rheumatology, Diakonhjemmet Hospital; I. Eshed, MD, Consultant

Radiologist, Sheba Medical Center, Tel Aviv University; F. Gandjbakhch, MD, Practising Rheumatologist, Department of Rheumatology, Pitié Salpêtrière Hospital, APHP, Université Paris 6-UPMC; S. Lillegraven, MD, Research Fellow, Department of Rheumatology, Diakonhjemmet Hospital, University of Oslo; P. Bird, BMed (Hons), FRACP, PhD, Grad Dip MRI, Senior Lecturer, University of NSW; V. Foltz, MD, Practising Rheumatologist, Department of Rheumatology, Pitié Salpêtrière Hospital, APHP, Université Paris 6-UPMC; A. Boonen, MD, PhD, Consultant Rheumatologist, Maastricht University Medical Center; M. Lassere, MBBS (Hons), PhD, Grad Dip Epi, FRACP, FAFPHM, Professor of Medicine, St. George Hospital, University of NSW; K-G. Hermann, MD, PhD, Consultant Radiologist, Department of Radiology, Charité University Hospital; A. Anandarajah, MD, Associate Professor of Medicine, Department of Allergy, Immunology and Rheumatology, University of Rochester Medical Center; U.M. Døhn, MD, PhD, Senior Registrar, Department of Rheumatology, Copenhagen University Hospitals at Hvidovre and Glostrup; J. Freeston, MD, NIHR Clinical Lecturer, Section of Musculoskeletal Disease, University of Leeds and NIHR Leeds Musculoskeletal Biomedical Research Unit; C.G. Peterfy,

MD, PhD, FRCP, Chief Executive Officer, Spire Sciences LLC; H.K. Genant, MD, FACP, FRCP, Professor Emeritus of Radiology, Medicine and Orthopaedics, University of California San Francisco, and Synarc, Inc.; E.A. Haavardsholm, MD, PhD, Senior Registrar, Diakonhjemmet Hospital, University of Oslo; F.M. McQueen, MBChB, MD, FRACP, Professor of Rheumatology, Department of Molecular Medicine and Pathology, Faculty of Medicine and Health Sciences, University of Auckland; P.G. Conaghan, MB, BS, PhD, FRACP, FRCP, Professor of Musculoskeletal Medicine, Section of Musculoskeletal Disease, University of Leeds and NIHR Leeds Musculoskeletal Biomedical Research Unit. Address correspondence to Dr. Østergaard; E-mail: mo@dadlnet.dk

Magnetic resonance imaging (MRI) is now frequently used as an outcome measure in rheumatoid arthritis (RA) clinical trials<sup>1,2</sup>. The OMERACT RA MRI score (RAMRIS), evaluating bone erosions, bone edema, and synovitis, is generally used in such trials. Evaluation of joint space narrowing (JSN) was omitted in the early phase of developing the RAMRIS during the late 1990s<sup>3</sup>, because the quality of MR images at that time was insufficient to evaluate cartilage thickness. However, MR images with higher signal and resolution are now available<sup>4,5</sup>. Cartilage damage is an important aspect of structural joint damage in RA, and a reliable MRI assessment system of JSN, reflecting cartilage loss, would further improve the usefulness of MRI in measuring outcome in RA clinical trials.

The aim of the present initiative was to develop and validate an OMERACT MRI assessment method of JSN in RA, which may be a useful adjunct to the current OMERACT RAMRIS.

## MATERIALS AND METHODS

The project, which was undertaken by the OMERACT MRI in Inflammatory Arthritis Task Force, had 3 phases.

**Phase A (multireader Exercise 1).** In a pilot study, coronal T1-weighted gradient echo MR images of unilateral wrist and metacarpophalangeal (MCP) joints from 5 patients with RA [4 women/1 man; median age 64 (range 30–68) yrs] and 3 controls [67% female; median age 33 (30–48) yrs] were scored 0–4 by a preliminary scoring system for JSN at 15 sites in the wrist and each of the 2nd–5th MCP joints, without reader pre-training or calibration, by 8 readers (7 readers read once, one reader twice), after circulation by DVD.

**Phase B.** After Exercise 1, the group held a half-day meeting in Philadelphia, in October, 2009. Results were presented, and selected images reviewed and discussed. At the meeting and during subsequent Web-based communication and teleconferences, agreement by consensus was achieved on an MRI definition of JSN, a revised scoring system, and reader rules.

**Phase C (multireader Exercise 2).** In this exercise, coronal T1-weighted 3D gradient echo MR images (voxel size 0.4 × 0.4 × 0.4 mm) of unilateral wrist and 2nd–5th MCP joints of a different cohort of 15 RA patients [12 women/3 men; median age 51 (33–78) yrs; disease duration 7 (4–22) yrs] and 4 controls [3 women/one man; age 36 (34–57) yrs] were scored for JSN by 5 readers (4 readers read once, one reader twice) using the revised score system (21 sites scored 0–4, see Figure 1 for scoring system). Radiographs of the same hand (wrist: 6 sites, MCP joints: 5 sites; PIP: 4 sites) were assessed by one reader according to the Sharp-van der Heijde (SvdH) scoring method for JSN (0: normal; 1: focal or doubtful; 2: generalized, > 50% of original joint space left; 3: generalized, < 50% of original joint space left; 4: ankylosis) and bone erosion<sup>6</sup>.

The reader who read MRI images twice was an experienced musculoskeletal radiologist, and MRI results for that reader (second read) were compared with radiographic JSN assessments, per joint space area and per

patient. One RA patient did not have complete radiographs available and was excluded from comparisons between MRI and radiographs.

Descriptive statistics, intraclass correlation coefficients (ICC; mixed effects, absolute agreement definition; average measure for intra-observer/interobserver agreements, single measure for intraobserver agreement/comparison between MRI and radiographs) and smallest detectable differences (SDD, for mean of readings) were calculated, using SPSS Statistics<sup>®</sup>, version 17.0.

## RESULTS

**Phase A: Multireader Exercise 1.** The intraobserver and interobserver ICC were 0.99 and 0.93, respectively, while the corresponding SDD were 2.8 JSN units [9.4% of maximal observed score (observed max)] and SDD 6.4 JSN units (4.9% of observed max).

**Phase B: Agreement on definition, scoring system, and reader rules.** Based on experiences from the small data set in Phase A, image review and discussion, consensus was reached on JSN definition (reduced joint space width compared to normal, as assessed in a slice perpendicular to the joint surface), scoring system [0–4 at 21 sites (17 wrist sites and each of 2nd–5th MCP joints, total range 0–84): 0: no narrowing; 1: focal or mild (< 33%) narrowing; 2: moderate (34%–66%) narrowing; 3: moderate to severe (67%–99%) narrowing; 4: ankylosis], and reader rules (Figure 1).

**Phase C: Multireader Exercise 2. MRI vs radiographs, per joint area.** The presence of JSN in each individual joint space area on MRI, as assessed by the experienced radiologist, and on radiographs, is shown in Table 1. On MRI, 111 of 294 (38%) areas in the RA patients were registered as having JSN (JSN score ≥ 1 in that specific area; Figure 2). When areas assessed by both MRI and radiography were compared (and trapezium-scaphoid and trapezoid-scaphoid joint spaces considered as one, as in the SvdH method), 54 joint spaces had JSN by MRI and 17 by radiography. Only 2 (1%) areas had JSN by radiography but not by MRI, while 39 (28%) had JSN on MRI but not radiography. MRI and radiography agreed in 99 areas (71%). The median difference between MRI and radiography scores in individual areas was 0, and the numerical difference never exceeded 2.

In healthy controls, JSN was noted at 12 (14%) joint spaces in total on MRI (0 on radiographs). Seven (58%) of these 12 areas were registered in the oldest control person (age 57 yrs).

**MRI vs radiography, per subject.** MRI JSN scores by the radiologist were median 7 (range 1–62) in RA patients and 2.5 (range 0–7) in healthy controls, whereas corresponding values were 0 (0–22) and 0 (0–0), respectively, for radiographs. It should be remembered that the areas assessed by MRI and radiography were not identical. The MRI JSN sum scores, including various joint space combinations (see below) are provided in Table 2.

The MRI and radiography total JSN scores (MRI<sub>Total</sub> and Xray<sub>SvdH-Total</sub>) were highly correlated (single-measures ICC 0.77, *p* < 0.001). When MRI and radiographic scores from identical areas were compared, ICC were 0.42 (*p* < 0.01) for 2nd–5th

OMERACT Joint Space Narrowing (JSN) scoring sheet							
	<b>MCP</b>	MCP2	MCP3	MCP4	MCP5		
	Score						
	<b>CMC</b>	CMC1	CMC2	CMC3	CMC4	CMC5	
	Score						
	<b>2.row</b>	TRM-TRD	TRD-CAP	CAP-HAM			
	Score						
	<b>1.-2.row</b>	TRM-SCA	TRD-SCA	CAP-SCA	CAP-LUN	HAM-TRI	
	Score						
	<b>1.row</b>	SCA-LUN	LUN-TRI				
	Score						
<b>Rad-Carp</b>	RAD-SCA	RAD-LUN					
Score							
<b>Definition of JSN</b>							
Reduced joint space width compared to normal, as assessed in a slice perpendicular to the joint surface							
<b>Scoring system (total range: 0-84)</b>							
JSN is scored 0-4 at each marked site							
0: No narrowing							
1: Focal or mild (<33%) narrowing							
2: Moderate (34% - 66%) narrowing							
3: Moderate to severe (67% - 99%) narrowing							
4: Ankylosis							
<b>Reader rules</b>							
Use coronal images							
Score at narrowest point							
On T1-weighted image: score "white (bone marrow fat) to white"							
If surface is eroded: Ignore erosions and measure "width if there had been no erosion"							
If joint with subluxation: Score despite deformities							

Figure 1. The OMERACT MRI joint space narrowing (JSN) scoring system: Score sheet, MRI definition, scoring system, and reader rules. MCP: metacarpophalangeal; CMC: carpometacarpal; TRM: trapezium; TRD: trapezoid; CAP: capitate; HAM: hamate; SCA: scaphoid; LUN: lunate; TRI: triquetrum; RAD: radius; ULN: ulna; SvdH: Sharp-van der Heijde.

MCP joints, and 0.83 ( $p < 0.001$ ) in wrists ( $MRI_{SvdH-wrist}$  vs  $Xray_{SvdH-wrist}$ ).

**MRI, intrareader reliability.** The mean (median/range) of readings 1 and 2 by the experienced radiologist was 13 (9/0–61), and 15 (5/0–62), respectively. The SDD (for mean of readings) was 6.8 JSN units, corresponding to 11.0% of the observed maximal score. The single measure intraobserver ICC for  $MRI_{total}$  was 0.90 (Table 2).

**MRI, interreader reliability.** The mean scores for the 19 subjects ranged from 11–25 for the 5 readers, whereas the median (min/max) ranged from 3–23 (0–10/62–71). The SDD (for mean of readings) was 6.2 JSN units, corresponding to 8.7% of the observed maximal score. The interobserver ICC for  $MRI_{total}$  was 0.92 (Table 2). ICC for different reader pairs are provided in Table 3.

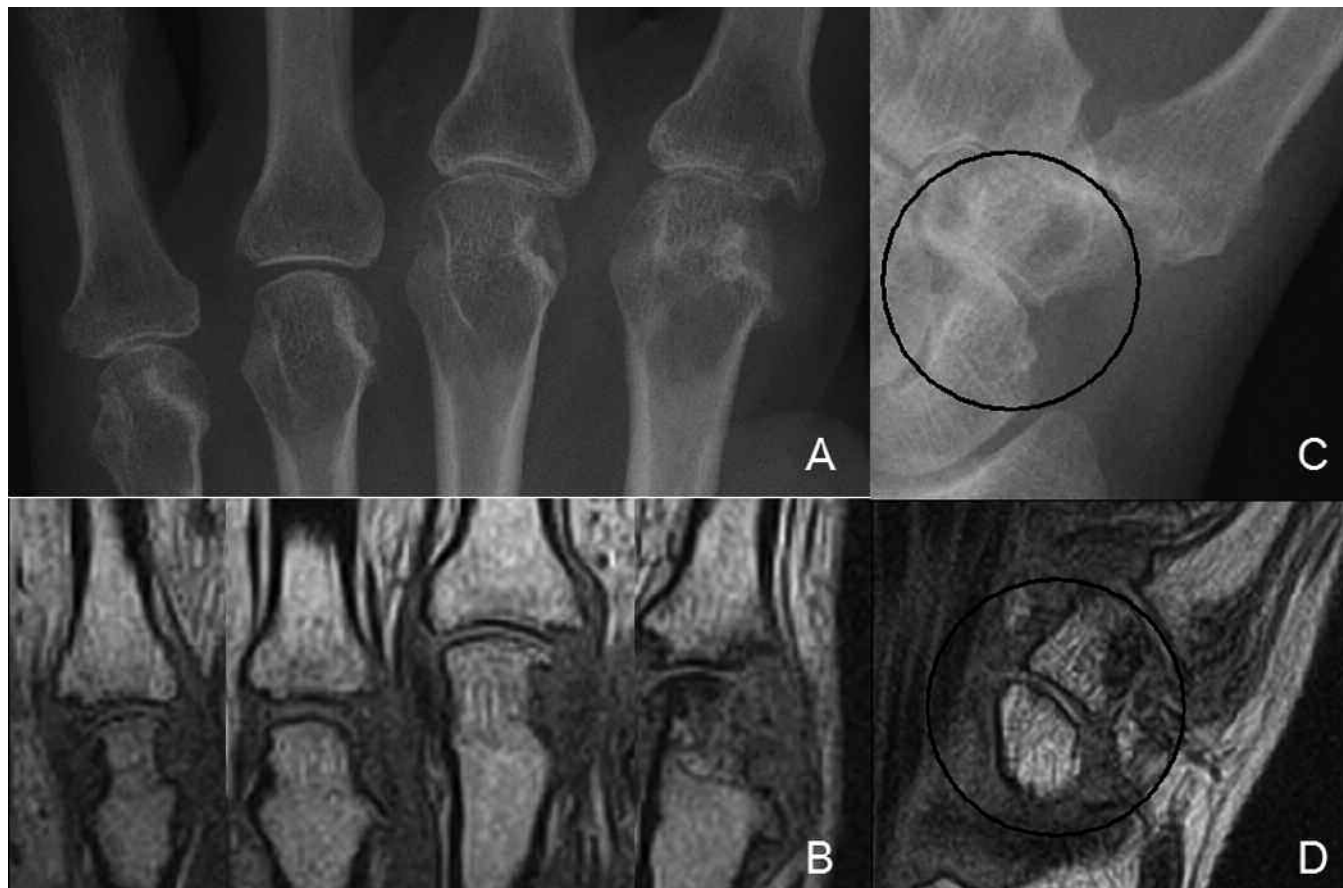
**Simplified MRI scoring methods.** The performance of various simplified scores was investigated. Table 2 provides intraobserver and interobserver ICC of separate MCP and wrist scorings and scorings of the joint spaces assessed by the SvdH and Sharp-Genant radiographic methods and by 2 further suggestions for simplified scores, assessing 14 and 7 joint spaces in the wrist, respectively. Table 2 explains which joint spaces are included in the different approaches. The score with only 7

assessed areas ( $MRI_{JSN7}$ , Table 2) demonstrated high correlation (ICC 0.79) with the total hand radiograph score ( $Xray_{SvdH-Total}$ ), and very good intra- and interobserver ICC ( $> 0.90$ ).

## DISCUSSION

We describe the first steps in developing and validating an MRI tool for assessment of JSN in RA joints, performed by experts with a mixed radiology/rheumatology background. The construct validity of the developed MRI JSN score was documented by a high correlation with its well validated radiographic counterpart, the SvdH JSN score. Its reliability was supported by high intraobserver and interobserver agreements, as assessed by ICC. Substantial reader variation in absolute score suggests further improvement may be gained from more extensive reader training and calibration in future studies. Simplified approaches evaluating fewer joint spaces demonstrated similar reliability and correlation with radiographic scores, as did the total scores, and may constitute useful, quicker alternatives. However, further testing in longitudinal studies is required.

A major strength of MRI is its tomographic perspective, and the resulting lack of projectional superimposition of bones and joint spaces. First, this allows for more detailed



*Figure 2.* Examples of radiography and MRI JSN scores. Radiographs in posterior-anterior projection (A and C) and coronal T1-weighted MR images (B and D) of the 2nd-5th MCP joints (A and B, 5th MCP joint on the left) and the radial aspect of the wrist (C-D). In the 2nd-5th MCP joint (right to left, in A and B), Sharp-van der Heijde (SvdH) radiographic JSN scores were 2, 0, 2, 3; and MRI JSN scores were 1, 0, 2, 2. The scaphoid-trapezoid/trapezium joint space (circles in C and D) was scored 1 by the SvdH radiographic score, and the scaphoid-trapezium bone was scored 1 by MRI JSN score. It should be noted that the MRI examination contains more slices than displayed here.

assessment of the areas included in the radiographic scoring systems. Further, it provides the opportunity to assess joint spaces that have been omitted from radiographic scores because of poor visualization. It remains to be determined whether the ability of MRI to assess more joint space areas in the wrist than radiography translates into a higher sensitivity to change.

A limitation of our study is its cross-sectional design. Registration of change over time is key in clinical trials and practice, and further studies are needed to explore the responsiveness and discriminatory capacity of the total MRI JSN score and its simplifications. Regarding feasibility, it should be mentioned that MRI is a more costly and time-consuming method for assessment of JSN than radiography. However, MRI simultaneously provides information about inflammation in synovium and bone that cannot be achieved by radiography, and the MRI sequence used for JSN assessment in this study does not prolong the MRI examination, as it is optimal for assessment of bone erosion.

Other MRI sequences, allowing better delineation of carti-

lage and separation of the cartilage on the adjoining bone surfaces, are available and may improve performance<sup>4,5</sup>. Our approach in this study was to use sequences that can be acquired on almost all units, without the requirement of a field strength and field homogeneity that allow robust fat suppression in all parts of the joints. Further, we envisage that JSN assessment will usually be done in conjunction with other RAMRIS assessments (synovitis, bone edema, and erosion) so it is advantageous to use common sequences suitable for all pathologies, to avoid very long MRI examination times.

JSN was registered in some areas in the healthy control population, in accordance with previous studies<sup>3</sup>. The radiologist found JSN in 12 areas in healthy controls, but this JSN never exceeded grade 1. Although the controls had no symptoms, it would be expected that mild JSN can occur, particularly with increasing age. In accordance with this, 7 of 12 areas with JSN in controls were noted in the oldest patient, a 57-year-old woman. Nevertheless, further study of healthy subjects, in different age groups and sex, is warranted.

ICC were calculated per reader pair since 2 readers are the

Table 1. JSN per joint space area in patients with RA as assessed by MRI† and radiography (Exercise 2, n = 14). All “Total” MRI JSN scores (MRI<sub>Total</sub>, MRI<sub>SvdHTotal</sub> and MRI<sub>Genant-Total</sub>) add the scores from MCP2-5 to the respective wrist scores.

	MRI (n = 294)		X-ray (n = 140)		JSN in Areas Assessed by X-ray (n = 140)				JSN in Areas Not Assessed by X-ray (n = 140)	Specific Wrist Joint Spaces Included in Simplified MRI Scores			
	Presence (Score ≥ 1)	Score, Median (Range)	Presence (Score ≥ 1)	Score, Median (Range)	Both X-ray and MRI	Neither X-ray nor MRI	X-ray, Not MRI	MRI, Not X-ray		SvdH	Genant	JSN14	JSN7
MCP2	5	0 (0–3)	2	0 (0–4)	2	9	0	3					
MCP3	5	0 (0–1)	1	0 (0–2)	1	9	0	4					
MCP4	4	0 (0–2)	1	0 (0–2)	0	9	1	4					
MCP5	4	0 (0–2)	1	0 (0–2)	1	10	0	3					
CMC1	5	0 (0–2)	–*	–*				5					
CMC2	4	0 (0–4)	–*	–*				4					
CMC3	11	1 (0–4)	2	0 (0–4)	2	3	0	9		X	X1/3	X	X
CMC4	6	0 (0–3)	1	0 (0–2)	1	8	0	5		X	X1/3	X	
CMC5	8	1 (0–3)	1	0 (0–1)	1	6	0	7		X	X1/3	X	
Trm-Trd	7	0.5 (0–4)	–*	–*				7					
Trd-Cap	11	1 (0–4)	–*	–*				11					X
Cap-Ham	8	1 (0–4)	–*	–*				8					X
Trm-Sca	4	0 (0–4)	–**	–**	–**	–**	–**	–**		X1/2		X	
Trd-Sca	5	0 (0–4)	3**	0 (0–4)**	3**	9**	0**	2**		X1/2		X	X
Cap-Sca	3	0 (0–4)	2	0 (0–4)	2	11	0	1		X	X1/2	X	
Cap-Lun	2	0 (0–4)	–*	–*				2			X1/2	X	X
Ham-Tri	4	0 (0–4)	–*	–*				4				X	X
Sca-Lun	3	0 (0–4)	–*	–*				3				X	X
Lun-Tri	5	0 (0–4)	–*	–*				5				X	
Rad-Sca	3	0 (0–2)	3	0 (0–3)	2	10	1	1		X	X1/2	X	X
Rad-Lun	4	0 (0–2)	–*	–*				4			X1/2	X	X
Sum	111	–	17	–	15	84	2	39***	53				

† MRI assessments by Reader 5 (experienced radiologist) are presented. \* Not assessed by radiography; \*\* Trm-Sca and Trd-Sca are analyzed as one area (as for the SvdH radiographic method). \*\*\* Only 10 separate joint spaces were included because the SvdH radiographic method assesses JSN in Trm-Sca and Trd-Sca as one area; therefore “n” in column 2 (294) is 14 higher than the sum of “n” in columns 6–9. X: Included in score with the weight of 1; X1/2: Included in score with the weight of 1/2; X1/3: Included in score with the weight of 1/3, in agreement with procedure in SvdH and Sharp-Genant radiographic scoring systems. MCP: metacarpophalangeal, CMC: carpometacarpal, Trm: trapezium, Trd: trapezoid, Cap: capitate, Ham: hamate, Sca: scaphoid; Lun: lunate; Tri: triquetrum, Rad: radius, Uln: ulna, JSN: joint space narrowing, SvdH: Sharp-van der Heijde.

Table 2. MRI JSN scores in patients with RA and healthy controls in Exercise 2: Distribution, intraobserver and interobserver agreement, and correlation with radiographic JSN scores. MRI scores, intraobserver ICC, and correlations with radiographic scores are given for the experienced musculoskeletal radiologist. Intraobserver ICC (only average measure ICC provided) are given for all 5 readers.

MRI JSN Score	Score Characteristics		Observed Scores, median (range)		Intraobserver Agreement		Interobserver Agreement ICC (average measure)	Agreement with X-ray <sub>SvdH-total</sub> ICC (single measure)
	No. Assessed Areas	Possible Range	RA	Controls	ICC (single measure)	ICC (average measure)		
MRI <sub>Total</sub>	21	0–84	7 (1–62)	2.5 (0–7)	0.90	0.95	0.92	0.77
MRI <sub>MCP2-5</sub>	4	0–16	1 (0–6)	0 (0–0)	0.79	0.89	0.86	0.15
MRI <sub>Wrist</sub>	17	0–68	5 (1–57)	2.5 (0–7)	0.92	0.96	0.93	0.84
MRI <sub>SvdH-total</sub>	11	0–40	2.8 (0–24)	1 (0–2.5)	0.87	0.93	0.90	0.75
MRI <sub>SvdH-wrist</sub>	7	0–24	2 (0–19)	1 (0–2.5)	0.92	0.96	0.94	0.68
MRI <sub>Genant-total</sub>	11	0–28	1.3 (0–13.3)	0.3 (0–0.7)	0.82	0.90	0.89	0.49
MRI <sub>Genant-wrist</sub>	7	0–12	0.7 (0–8.3)	0.3 (0–0.7)	0.89	0.94	0.95	0.35
MRI <sub>OM14</sub>	14	0–56	5 (1–48)	2.5 (0–5)	0.93	0.96	0.93	0.89
MRI <sub>OM7</sub>	7	0–28	1 (1–22)	1.5 (0–2)	0.91	0.95	0.95	0.79

SvdH: Sharp-van der Heijde; ICC: intraclass correlation coefficient. See Table 1 for description of joint spaces included in the various MRI JSN scores.

most likely number for clinical trials. The presented values are average measure ICC (Table 3) and reflect the reliability of readings for pairs of readers.

Previous studies have, in agreement with our results, reported that MRI and radiographic assessment of JSN correlate well<sup>4,5,7</sup>. The correlation between MRI and radiographic

*Table 3.* Interreader reliability (intraclass correlation coefficients, ICC) per reader pair (Exercise 2). Key to ICC values: Very good, ICC  $\geq 0.80$ ; good:  $0.50 \leq \text{ICC} < 0.80$ ; poor:  $0.20 \leq \text{ICC} < 0.50$ ; trivial:  $\text{ICC} < 0.20$ ; values are average measure ICC. Readers 1 to 4 have rheumatological background, while Reader 5 is a musculoskeletal radiologist. Median interreader ICC 0.83.

Reader	Reader 1	Reader 2	Reader 3	Reader 4	Reader 5, 1st Read
Reader 1					
Reader 2	0.83				
Reader 3	0.82	0.92			
Reader 4	0.63	0.87	0.80		
Reader 5, 1st read	0.74	0.89	0.80	0.96	
Reader 5, 2nd read	0.63	0.85	0.78	0.90	0.95*

\* Intrareader ICC for Reader 5.

scores of JSN were higher in wrists than in MCP joints. This may be at least partly explained by the higher mobility between bones in the MCP joints, with the result that these joints, despite stipulating full extension, may be imaged in different degrees of flexion, compromising reliable assessment of JSN. This highlights the need for exact and meticulous positioning of finger joints in the extended position if JSN assessment is planned, preferably using a dedicated splint. It also encourages further work on refining the scoring procedure in joints where full extension is not possible, and/or have subluxation and/or severe destruction.

An MRI scoring system of JSN in RA wrist and MCP joints was developed and showed construct validity and good intra- and interreader reliability. The system may, after further validation in longitudinal data sets, be useful as an outcome measure to assess cartilage damage in RA, and may thereby further improve the usefulness of MRI in RA clinical trials.

## REFERENCES

1. Østergaard M, Peterfy C, Conaghan P, McQueen F, Bird P, Ejbjerg B, et al. OMERACT rheumatoid arthritis magnetic resonance imaging studies. Core set of MRI acquisitions, joint pathology definitions, and the OMERACT RA-MRI scoring system. *J Rheumatol* 2003;30:1385-6.
2. Haavardsholm EA, Østergaard M, Ejbjerg BJ, Kvan NP, Uhlig TA, Lilleas FG, et al. Reliability and sensitivity to change of the OMERACT rheumatoid arthritis magnetic resonance imaging score in a multireader, longitudinal setting. *Arthritis Rheum* 2005;52:3860-7.
3. Østergaard M, Klarlund M, Lassere M, Conaghan P, Peterfy C, McQueen F, et al. Interreader agreement in the assessment of magnetic resonance images of rheumatoid arthritis wrist and finger joints — an international multicenter study. *J Rheumatol* 2001;28:1143-50.
4. McQueen F, Clarke A, McHaffie A, Reeves Q, Williams M, Robinson E, et al. Assessment of cartilage loss at the wrist in rheumatoid arthritis using a new MRI scoring system. *Ann Rheum Dis* 2010;69:1971-5.
5. Peterfy C, DiCarlo J, Olech E, Bagnard MA, Gabriele A, Gaylis NB. Evaluating joint space narrowing in rheumatoid arthritis using MRI [abstract]. *Ann Rheum Dis* 2009;68 Suppl 3:89.
6. van der Heijde D. How to read radiographs according to the Sharp/van der Heijde method. *J Rheumatol* 1999;26:743-5.
7. Taouli B, Zaim S, Peterfy CG, Lynch JA, Stork A, Guermazi A, et al. Rheumatoid arthritis of the hand and wrist: comparison of three imaging techniques. *AJR Am J Roentgenol* 2004;182:937-43.