

Magnetic Resonance Imaging in Rheumatoid Arthritis — Advances and Research Priorities

MIKKEL ØSTERGAARD, FIONA M. McQUEEN, PAUL BIRD, BO EBJJERG, MARISSA N.D. LASSERE, CHARLES G. PETERFY, PHILIP J. O'CONNOR, ESPEN HAAVARDSHOLM, RON SHNIER, HARRY K. GENANT, PAUL EMERY, JOHN P. EDMONDS, and PHILIP G. CONAGHAN

ABSTRACT. This article updates the work and results of the OMERACT MRI in RA Working Group as presented at the OMERACT 7 meeting in May 2004, focusing on the development of the EULAR-OMERACT rheumatoid arthritis magnetic resonance imaging reference image atlas, and on areas for future research. (J Rheumatol 2005;32:2462–4)

Key Indexing Terms:

MAGNETIC RESONANCE IMAGING
EROSIONS SYNOVITIS

RHEUMATOID ARTHRITIS
BONE EDEMA OMERACT

Introduction

OMERACT is concerned with the adequacy of outcome measures used in rheumatology clinical trials¹. Structural joint damage, a major outcome in rheumatoid arthritis (RA), has traditionally been measured by scoring methods applied to radiological images². However, radiography only visualizes the late signs of preceding disease activity. Magnetic

resonance imaging (MRI) can detect RA erosive change with greater sensitivity than conventional radiography, particularly in early disease. In addition, MRI allows direct visualization and assessment of synovitis, the primary lesion in RA, and in bone edema, a probable forerunner of bone erosion^{3,4}. Given these advantages, the critical issue remains how best to use MRI as an outcome measure in RA clinical trials.

From the Copenhagen University Hospitals at Herlev and Hvidovre, Copenhagen, Denmark; Department of Rheumatology, Auckland University, Auckland, New Zealand; Department of Rheumatology, University of NSW, Sydney, Australia; Copenhagen University; Department of Rheumatology, St. George Hospital, University of NSW, Sydney, Australia; Synarc Inc., San Francisco, CA, USA; Department of Radiology, Leeds General Infirmary, Leeds, UK; Diakonhjemmet Hospital, University of Oslo, Oslo, Norway; Department of Diagnostic Imaging, Mayne Nickless, Sydney, Australia; University of California, San Francisco, CA, USA; and the Academic Unit of Musculoskeletal Disease, University of Leeds, Leeds, UK.

M. Østergaard, MD, PhD, DMSc, Professor in Rheumatology/Arthritis, Copenhagen University Hospitals at Herlev and Hvidovre; F.M. McQueen, MD, FRACP, Associate Professor in Rheumatology, Department of Rheumatology, Auckland University; P. Bird, BMed (Hons), FRACP, Consultant Rheumatologist, Department of Rheumatology, University of NSW; B. Ejjbjerg, MD, PhD, Research Fellow, Copenhagen University Hospital at Hvidovre; M.N.D. Lassere, MB, BS, Grad Dip Epi, PhD, FRACP, FAFPHM, Associate Professor in Medicine, Department of Rheumatology, St. George Hospital, University of NSW; C.G. Peterfy, MD, PhD, Chief Medical Officer, Synarc Inc.; P.J. O'Connor, MB, BS, MRCP, FRCP, Consultant Skeletal Radiologist, Department of Radiology, Leeds General Infirmary; E.A. Haavardsholm, MD, Research Fellow, Diakonhjemmet Hospital, University of Oslo; R. Shnier, MBBS, FRACP, National Director of Diagnostic Imaging, Department of Diagnostic Imaging, Mayne Nickless; H.K. Genant, MD, FACR, FRCP, Professor of Radiology, University of California; P. Emery, MA, MD, FRCP, ARC Professor in Rheumatology, Academic Unit of Musculoskeletal Disease, University of Leeds; J.P. Edmonds, MB, BS, MA, FRACP, Director, Professor of Rheumatology, Department of Rheumatology, University of NSW; P.G. Conaghan, MB, BS, FRACP, FRCP, Professor of Musculoskeletal Medicine, Academic Unit of Musculoskeletal Disease, University of Leeds.

Address reprint requests to Dr. M. Østergaard, Department of Rheumatology, Hvidovre Hospital, Kettegaard alle 30, DK-2650 Hvidovre, Denmark.

The OMERACT MRI in RA Working Group

Since 1998 an international OMERACT MRI in RA working group has aimed at developing MRI scoring systems to assess RA synovitis and damage, which would satisfy the elements of the OMERACT filter (truth, discrimination, and feasibility)¹. The group's work has largely (but not exclusively) focused on semiquantitative assessments in RA. MRI definitions of important RA joint pathologies and a "core set" of basic MRI sequences to be used for imaging of the RA joint have been suggested, in order to increase comparability between future studies⁵. Further, based on a series of studies⁶⁻⁸, an RA MRI scoring system (OMERACT 2002 Rheumatoid Arthritis MRI Score, RAMRIS) for evaluation of inflammatory and destructive changes in RA hands and wrists was presented at OMERACT 6 in Brisbane, Australia, in April 2002. OMERACT 6 participants endorsed the OMERACT 2002 RAMRIS as a standard comparator for new/alternative MRI methods for RA assessment and encouraged its further testing in longitudinal studies⁹.

At the 2002 American College of Rheumatology meeting the next task of the group was decided. The group felt that the performance and generalizability of RAMRIS scoring could probably be improved by availability of a set of standard reference images (or atlas). On this basis it was decided to focus the group's mutual efforts in the next 18 months on developing a reference film atlas to be used for scoring

RA joint pathology. At the same time responsibility of chairing the group was passed on from John Edmonds and Marissa Lassere (both from Sydney) to Mikkel Østergaard (Copenhagen) and Philip Conaghan (Leeds).

The EULAR-OMERACT RA MRI Reference Image Atlas

The use of the RAMRIS scoring system by outside investigators has been hampered by a lack of standard images of each grade. The reference film atlas was intended to create a new tool for standardized assessment of RA joints that would allow scoring of MR image sets for inflammatory and destructive changes according to the best possible match with standard reference images such as the Larsen method for scoring of radiographs¹⁰. This approach is expected to increase opportunities for standardized reproducible scoring, and for comparability of MRI scoring results between centers and between studies.

Based on the previously developed RA MRI scoring system⁵, the group agreed on features, joints, image types, and imaging planes that would in their opinion best illustrate the scoring system in an atlas. Providing examples of every grade of every feature for every bone in the wrist and metacarpophalangeal (MCP) joints was considered unnecessary and excessive. It was decided instead to illustrate synovitis in one MCP joint and each of the 3 wrist joint areas scored in the RAMRIS (distal radioulnar, radiocarpal, and intercarpal-carpometacarpal areas), while illustrating bone edema and bone erosions in the one phalangeal base, one metacarpal head, one metacarpal base, capitate, scaphoid, lunate, triquetrum, and radius.

After collecting at least 3 representative examples of each grade for each RA pathology, the team met for a 3-day period in Sydney, Australia, to review the images, and choose by consensus the most illustrative set for each feature, site, and grade. A predefined subset of images (e.g., for erosions: all coronal slices through the bone) was then extracted (Figure 1). These images were then reread by all observers (by consensus) to confirm the scores originally assigned. Subsequently, all selected images (about 1050 images) were photographed and formatted at Hvidovre Hospital, Denmark. Finally, in Spring 2004 the images were distributed to all readers for final approval. The atlas is published as a supplement to the *Annals of the Rheumatic Diseases*, with financial support from EULAR¹¹.

OMERACT 7 Special Interest Group Session on MRI in RA

During the OMERACT 7 meeting in Asilomar, May 2004, a series of meetings were held by the working group, focusing on finalization of the atlas project, preparation of the plenary session, and discussing future research priorities. At the session, the status, recent advances, and potential research priorities concerning MRI as an outcome measure in RA were addressed.

Prior to OMERACT 7, the group was concerned about a somewhat negative impression having been conveyed about interreader reliability, based on the group's previous uncalibrated multireader exercises⁶⁻⁸. The worry was that the interreader reliability in these studies, which was lower than in studies with fewer and calibrated readers^{12,13}, would be overly attributed to the RAMRIS scheme itself rather than viewed in light of the conditions of the exercises that were done, including factors such as the acquisition protocol, quality of the images used, the use of hard-copy films rather than computerized image display systems, and most important, the lack of formal calibration of the multiple readers involved. With this in mind, the Special Interest Group session opened with a number of presentations to update participants on the current status of MRI as an outcome measure in RA, including to which extent the OMERACT RAMRIS meets the OMERACT filter. This status is described in these proceedings as a separate article⁴. Subsequently, the atlas project (see above) was presented¹¹.

Remaining scientific questions of importance to the use of MRI as an outcome measure in RA were then discussed, aiming at exploring OMERACT participants' views on the future research priorities for the OMERACT MRI in RA group.

A number of potential research areas were suggested by group members and other OMERACT participants:

Potential Research Areas for the OMERACT MRI in RA Group

- Completion of atlas project (in progress)
- Testing of the atlas
- Development of training set for RAMRIS scoring
- Dedicated extremity MRI units (value of low cost, low field units)
- MRI without contrast agent injection
- Optimal joint selection (which/how many?)
- Sensitivity to change of MRI approaches vs other modalities
- Alternative MRI evaluation methods (semiquantitative/quantitative)
- Validation against other methods (pathology, computerized tomography, ultrasonography)
- Other structures/types of pathologies (e.g., cartilage, tenosynovitis)
- New techniques (e.g., new sequences, quantification)

Conclusion and Future Plans

The OMERACT MRI in RA group has suggested MRI definitions of the important RA joint pathologies, a "core set" of basic MRI sequences, and a scoring system (OMERACT 2002 RAMRIS) for evaluation of RA finger and wrist joints. A EULAR-OMERACT RA MRI reference image atlas, allowing scoring of MR images for inflammatory and

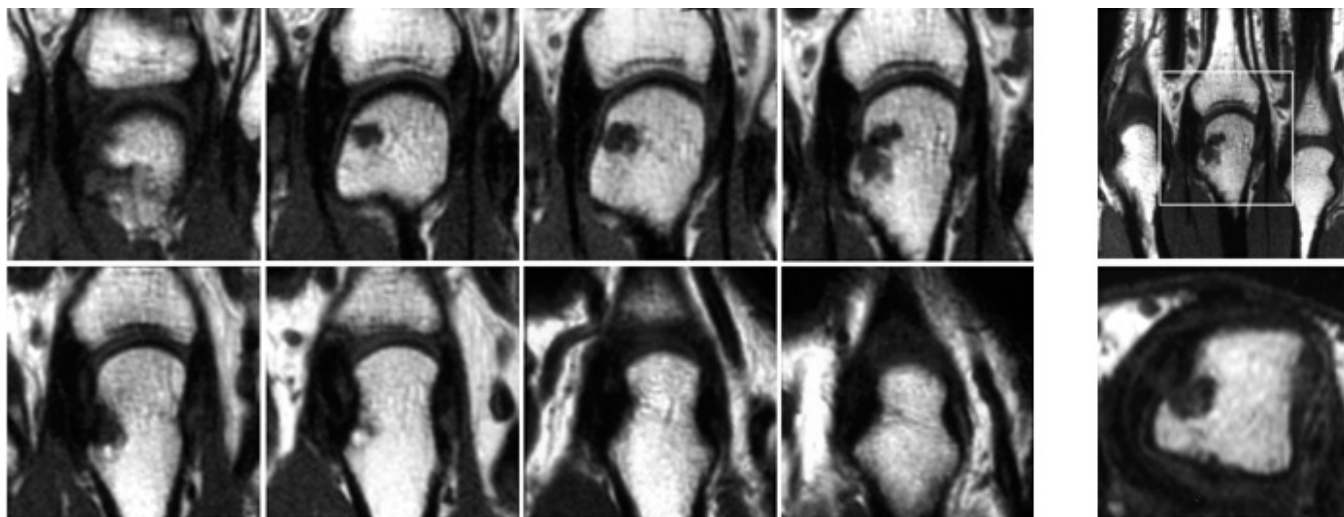


Figure 1. Grade 2 bone erosion in the third metacarpal head, according to the EULAR-OMERACT RA MRI reference image atlas. The 8 images at left are adjacent coronal slices through the metacarpal head. From these coronal images the percentage of eroded bone, as compared with the volume of original bone from the joint surface to a depth of 1 cm, is estimated. In this case, the erosion volume is estimated to be within the 11–20% (grade 2) range. The 2 images on the right are a coronal scout image (top) and an axial image (bottom) to confirm that the erosion, as required by definition, is visible in 2 planes.

destructive changes guided by standard reference images, has been developed¹¹. The evidence for the usefulness of MRI as an outcome measure in proof-of-concept RA studies is presented separately⁴.

The OMERACT MRI in RA group will continue its mutual efforts to explore and improve MRI as an outcome measure in RA. Short-term research priorities will be to test the atlas. Longer-term research priorities of the group include the study of the validity of MRI using low cost, low field dedicated extremity magnets, and development of a semiquantitative tool for MRI assessment of peripheral joints in psoriatic arthritis.

REFERENCES

1. Boers M, Brooks P, Strand CV, Tugwell P. The OMERACT filter for outcome measures in rheumatology. *J Rheumatol* 1998;25:198-9.
2. van der Heijde DMFM. Plain x-rays in rheumatoid arthritis: overview of scoring methods, their reliability and applicability. *Bailleres Clin Rheumatol* 1996;10:435-53.
3. McQueen FM, Stewart N, Crabbe J, et al. Magnetic resonance imaging of the wrist in early rheumatoid arthritis reveals progression of erosions despite clinical improvement. *Ann Rheum Dis* 1999;58:156-63.
4. Conaghan P, McQueen F, Peterfy C, et al. The evidence for MRI as an outcome measure in proof-of-concept rheumatoid arthritis studies. *J Rheumatol* 2005;32:2465-9.
5. Ostergaard M, Peterfy C, Conaghan P, et al. OMERACT rheumatoid arthritis magnetic resonance imaging studies. Core set of MRI acquisitions, joint pathology definitions, and the OMERACT RA-MRI scoring system. *J Rheumatol* 2003;30:1385-6.
6. Ostergaard M, Klarlund M, Lassere M, et al. Interreader agreement in the assessment of magnetic resonance images of rheumatoid arthritis wrist and finger joints — an international multicenter study. *J Rheumatol* 2001;28:1143-50.
7. Conaghan P, Lassere M, Østergaard M, et al. OMERACT rheumatoid arthritis magnetic resonance imaging studies. Exercise 4: an international multicenter longitudinal study using the RA-MRI Score. *J Rheumatol* 2003;30:1376-9.
8. Lassere M, McQueen F, Østergaard M, et al. OMERACT rheumatoid arthritis magnetic resonance imaging studies. Exercise 3: an international multicenter reliability study using the RA-MRI Score. *J Rheumatol* 2003;30:1366-75.
9. McQueen F, Lassere M, Edmonds J, et al. OMERACT rheumatoid arthritis magnetic resonance imaging studies. Summary of OMERACT 6 MR Imaging Module. *J Rheumatol* 2003;30:1387-92.
10. Larsen A, Dale K, Eek M. Radiographic evaluation of rheumatoid arthritis and related conditions by standard reference films. *Acta Radiol Diagn* 1977;18:481-91.
11. Ostergaard M, Edmonds J, McQueen J, et al. An introduction to the EULAR-OMERACT rheumatoid arthritis MRI reference image atlas. *Ann Rheum Dis* 2005;64 Suppl 1:i3-7.
12. O'Connor P, Østergaard M, Klarlund M, et al. Longitudinal evaluation of MRI scoring in rheumatoid arthritis — an international multicenter study of interreader agreement [abstract]. *Arthritis Rheum* 2001;44 Suppl:S315.
13. Bird P, Lassere M, Shnier R, Edmonds J. Computerized measurement of magnetic resonance imaging erosion volumes in patients with rheumatoid arthritis: a comparison with existing magnetic resonance imaging scoring systems and standard clinical outcome measures. *Arthritis Rheum* 2003;48:614-24.